

変形性関節症
レポート③

自己間葉系幹細胞
を変形性膝関節症
患者6名へ関節内投
与による臨床報告

Mohsen Emadedin MD ,et .al .
Intra-articular Injection of
Autologous Mesenchymal
Stem Cells in Six Patients
with Knee Osteoarthritis
Archives of Iranian Medicine,
Volume 15, Number 7, July
2012

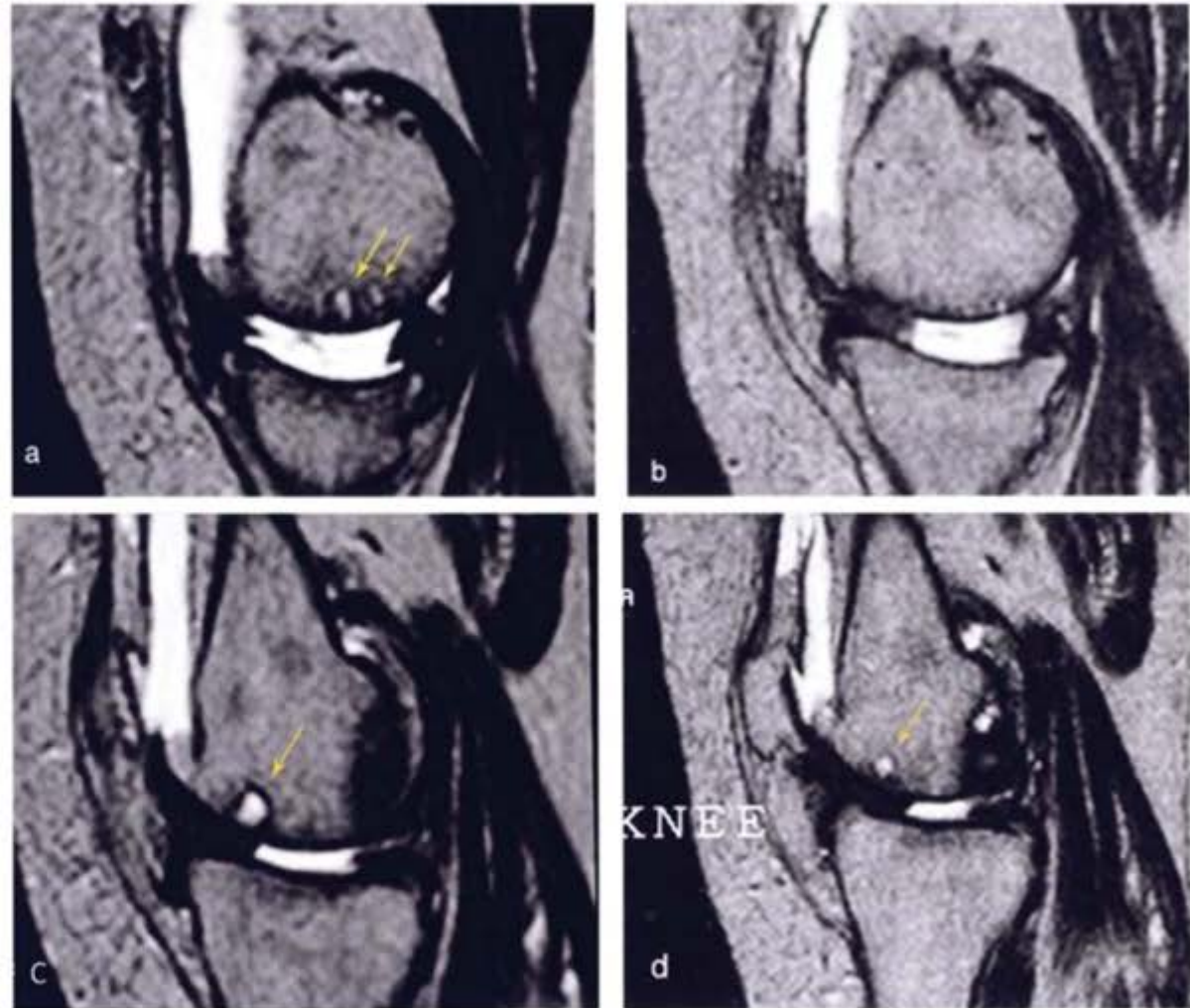


Figure 5. Sagittal MRI of the knee in a 65-year-old female patient with OA. Arrows in a and c show areas of increased signal intensity related to subchondral edema. Six months post-injection, MRI shows disappearance (b) or distinct decrease (d) of the size of these areas.